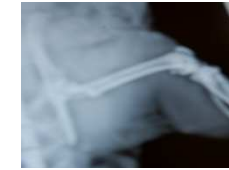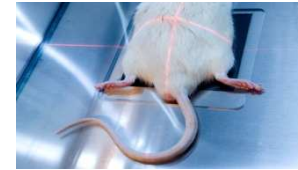


STUDY TITLE :

MICE EXPERIMENTAL MODEL OF OSTEOSARCOMA



Protocol study



Animals:

Mice

Age :

4 weeks (upon delivery)

Weight:

18 - 20 g

Sex :

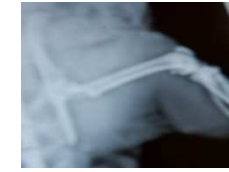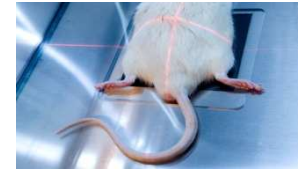
Male

Strain :

C3He

Supplier :

Charles River Laboratories or Elevage Janvier

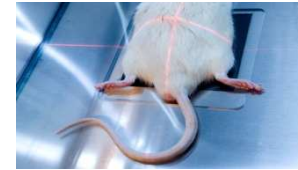


Induction of the pathology:

- ✓ Injection of POS-1 cells in mice tibiae
- ✓ Mice develop a primary tumor on the injection site within 2-3 weeks
- ✓ Small fragments provided from a single tumor are transplanted to the mice in close contact with the tibia
- ✓ Tumors appeared at the graft site approximately 8 days later
- ✓ The tumor that develops in contact to the tibia induces osteolytic lesions that reproduce the osteolytic form of human osteosarcoma



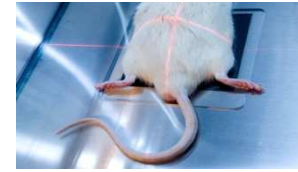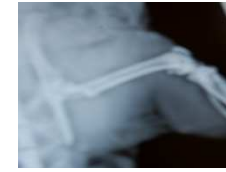
Treatment



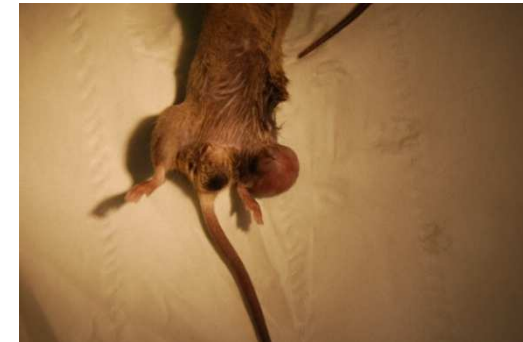- ✓ Any administration route
- ✓ Treatment to be defined with the sponsor (start and frequency)



Clinical follow-up

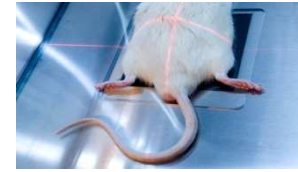


- ✓ Weight evolution
- ✓ General clinical state
- ✓ Detailed clinical examinations
- ✓ Reaction to compound administration
- ✓ Tumor volume measurement





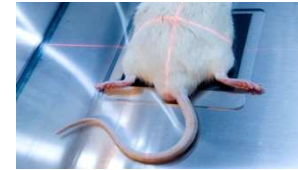
Biological follow-up



- ✓ ELISA assays on serum bone makers on 96 well plates in duplicate
- ✓ Serum markers of bone resorption measurement : CTX, TRAP 5b,...



Radiological follow-up

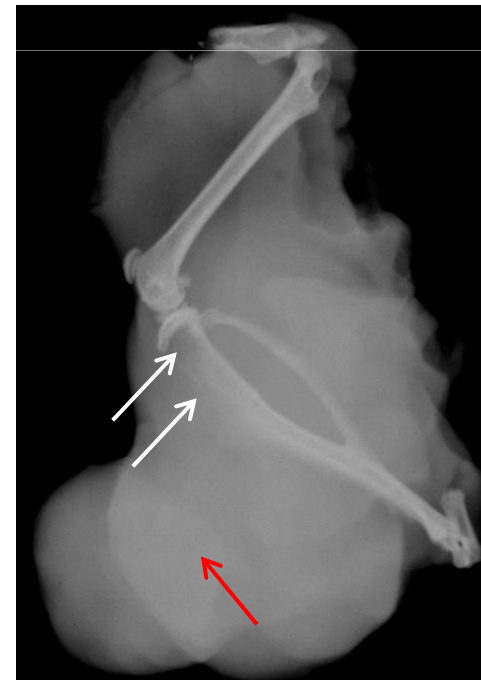


✓ Kinetic of radiographical analyses

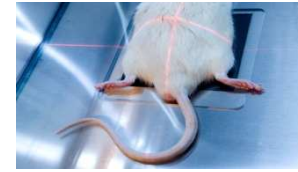


✓ Scoring of radiographies:

Scoring	Osteolysis degree
0	No visible osteolysis
1	Low
2	Average
3	High
4	Strong



Mice experimental model of osteosarcoma - ABS

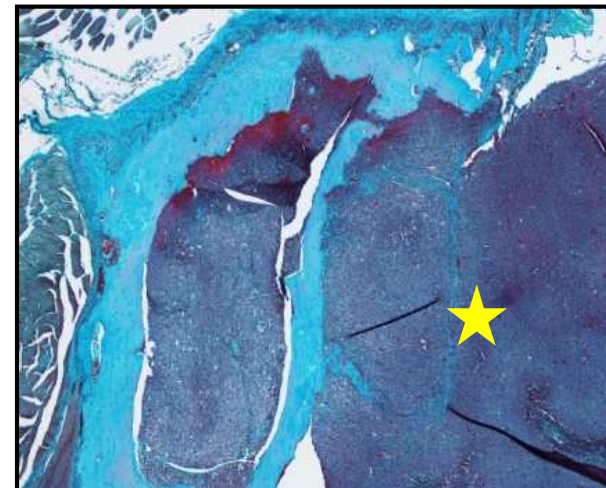

- ✓ Animals euthanized at the end of the study
- ✓ Histological analyses performed on tibiae
- ✓ Samples embedded in resin or in paraffin after decalcification :

→ Stainings proposed:

- TRAP staining / PARAFFIN
- Masson's Trichrome staining/ PARAFFIN
- Hematoxilin / Eosin / PARAFFIN
- Goldner's Trichome staining / RESINE
- Von Kossa staining / RESINE

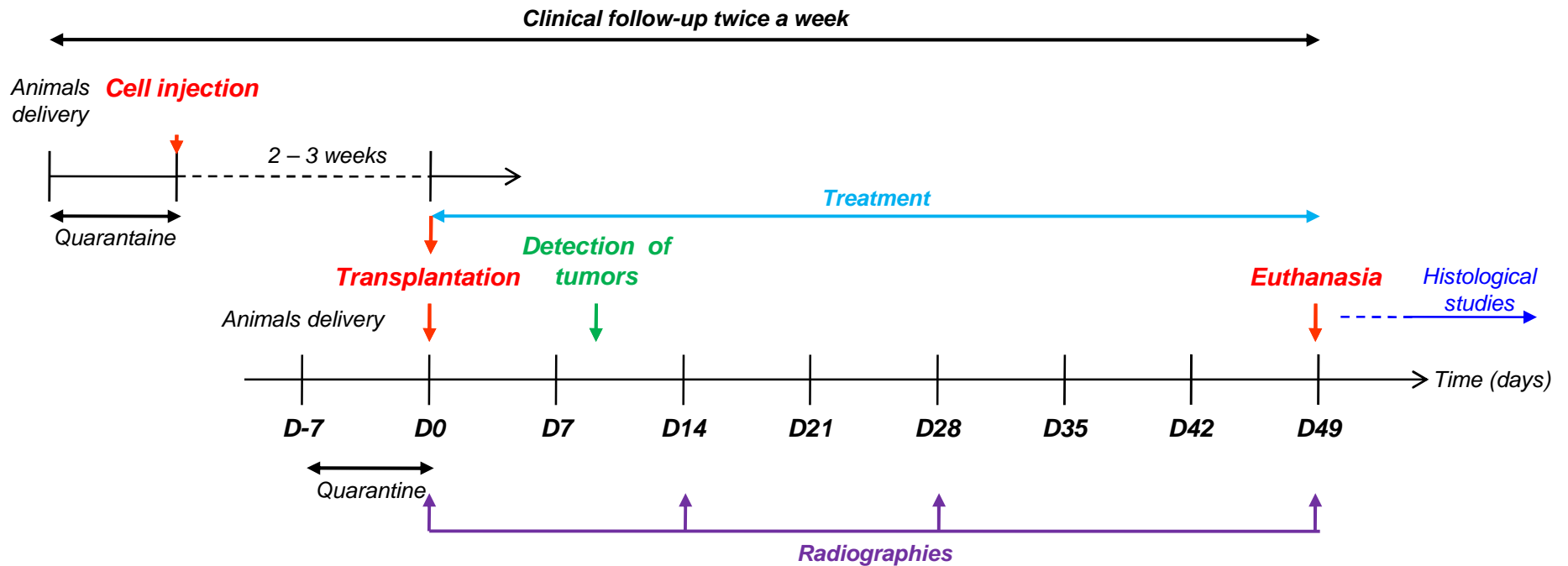
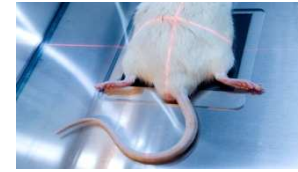
Other stainings are available



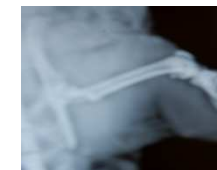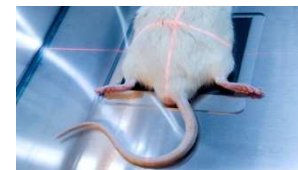Tumor burden (yellow star)



Synopsis (example)



Mice experimental model of osteosarcoma - ABS



Ronan LE BOT – CEO

ronan.lebot@atlantic-bone-screen.com

Florence DAUBINE, PhD – Project Manager

florence.daubine@atlantic-bone-screen.com

Fabien PETIT – Project Manager

fabien.petit@atlantic-bone-screen.com

Elisabeth PORCHER – Business Development Manager

elisabeth.porcher@atlantic-bone-screen.com

ATLANTIC BONE SCREEN SAS

1, rue Gaston Veil

44000 Nantes

France

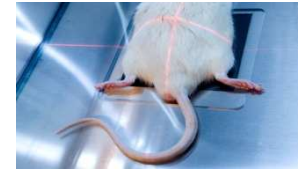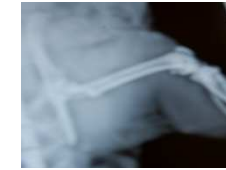
www.atlantic-bone-screen.com

Tel : +33(0)2 40 41 11 25

Fax : + 33(0)2 40 41 28 35

Contact us...

... And we will send you a tailor-made protocol study

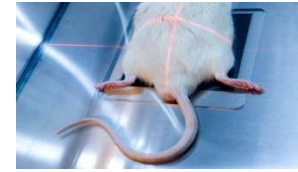


IN VIVO STUDY :

RAT EXPERIMENTAL MODEL OF OSTEOSARCOMA



Protocol study



Animals:

Rats

Age:

4 weeks old (upon delivery)

Sex:

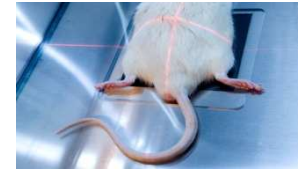
Male

Strain:

Sprague Dawley

Supplier:

Charles River Laboratories

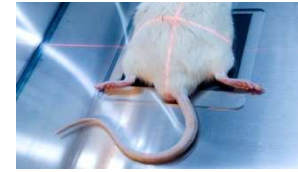


Induction of the pathology:

- ✓ Removal of the rat donor tumor
- ✓ Implantation of a 10 mm³ fragment in the paratibial muscle
- ✓ Development of a tumor for 80% to 100% of animals, around 4 weeks after transplantation



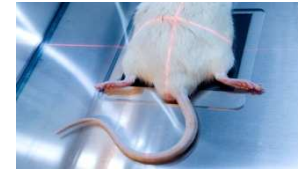
Treatment



- ✓ Any administration route
- ✓ Treatment to be defined with the sponsor (start and frequency)



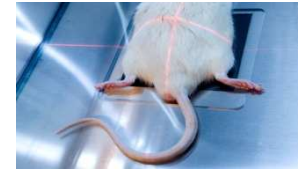
Clinical follow-up



- ✓ Weight evolution
- ✓ General clinical state
- ✓ Detailed clinical examinations
- ✓ Reactions after surgery and reaction to compound administration
- ✓ Tumor volume measurement



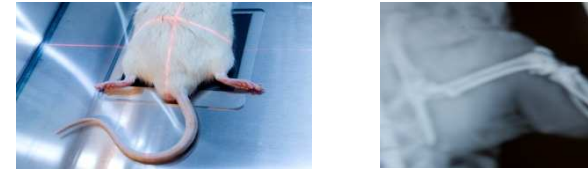Biological follow-up



- ✓ ELISA assays of serum makers on 96 well plates in duplicate
- ✓ Serum markers of bone resorption measurement : CTX, TRAP 5b,...
- ✓ Serum markers of bone formation measurement : PAL, Osteocalcin,...



Radiological follow-up

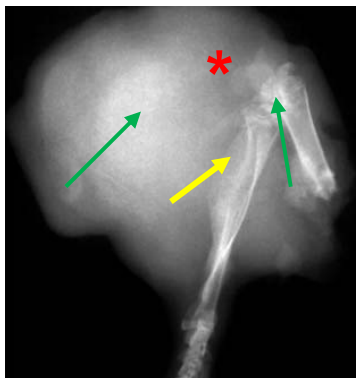


✓ Kinetic of radiographical analyses



Scoring	Osteolysis degree
0	No visible bone metastases
1	Low bone metastases
2	Average bone metastases
3	High bone metastases
4	Strong bone metastases

✓ Scoring of radiographs:

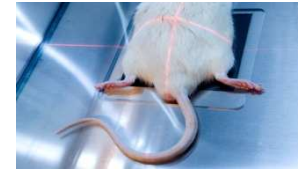


- * Tumor burden
- Osteolysis
- Ectopic bone formation

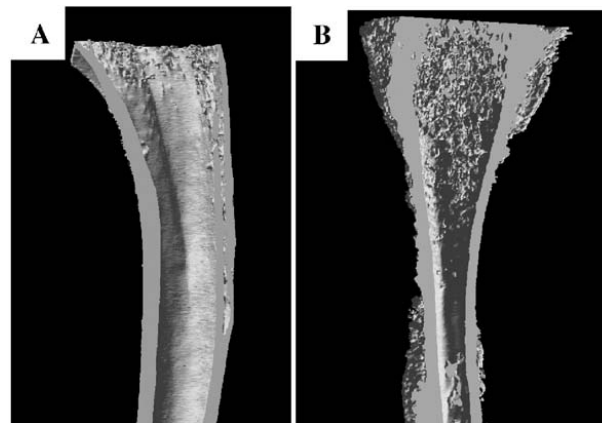
Rat experimental model of osteosarcoma - ABS



Microscanner analyses



- ✓ Qualitative and quantitative analysis by microtomography (Skyscan 1076)
- ✓ 3 dimension analysis of the sample
- ✓ Study of the trabecular architecture
- ✓ Non destructive technique (sample usable for other tests)



Control

Bone deformation

Rat experimental model of osteosarcoma - ABS

Histological analyses



- ✓ Animals euthanized at the end of the study
- ✓ Histological analyses performed on both femora
 - Left femur = “control”
 - Right femur = “tumor”

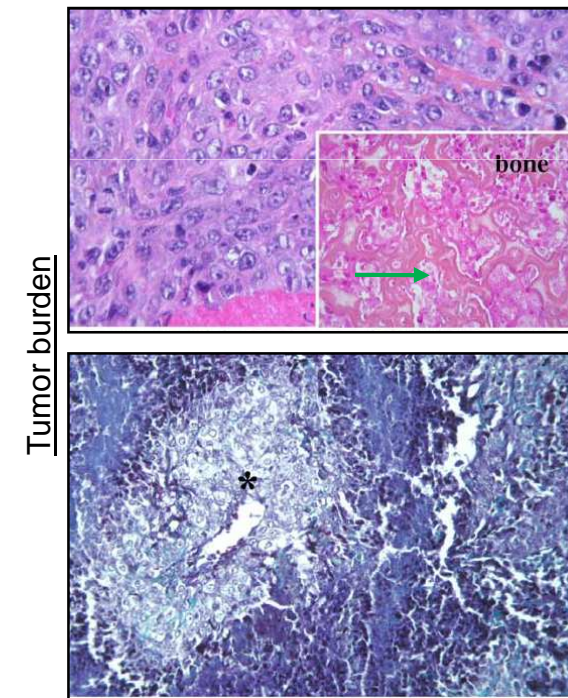
- ✓ Samples embedded in resin or paraffin :

→ Stainings proposed:

- Von Kossa staining (bone structure)/ RESIN
- Goldner’s trichrome staining/ RESIN
- TRAP staining/ PARAFFIN
- Masson’s Trichrome staining / PARAFFIN
- Hematoxiline/Eosine or Fushine / PARAFFIN or RESIN

N.B. : Other stainings are available

Rat experimental model of osteosarcoma - ABS

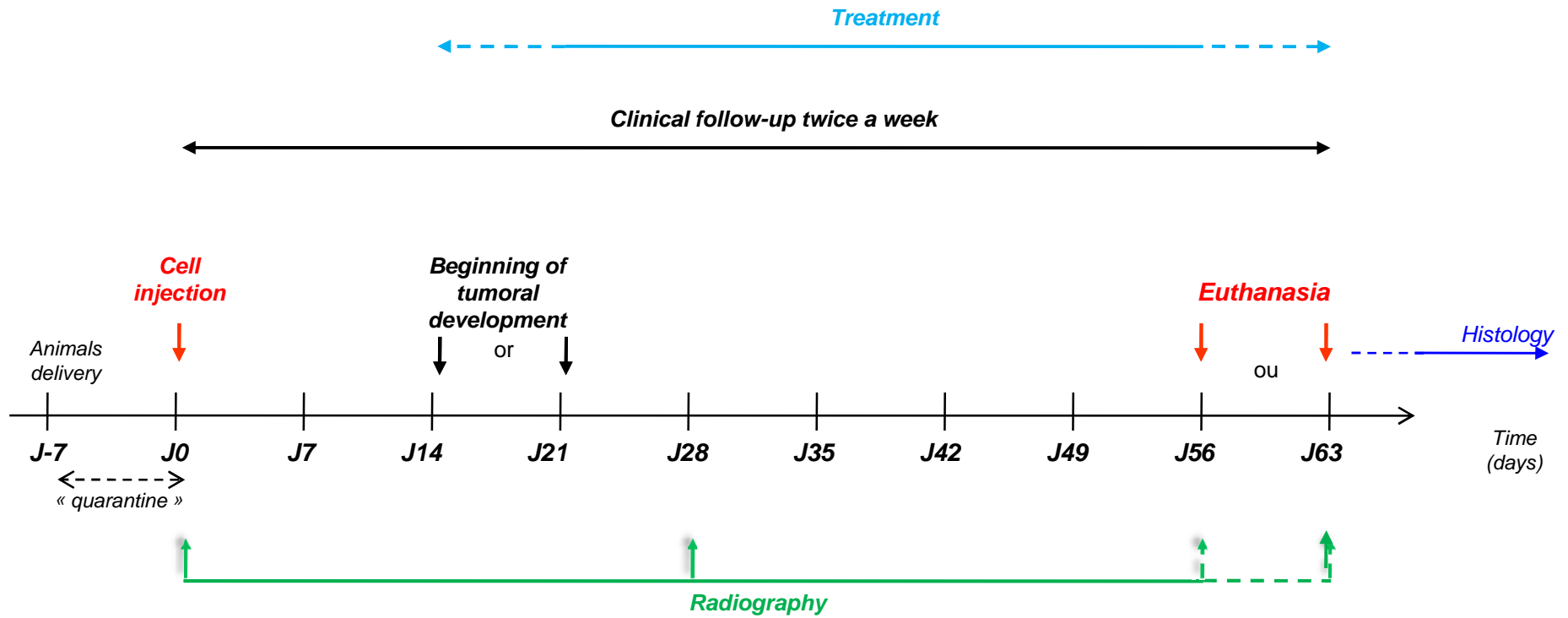
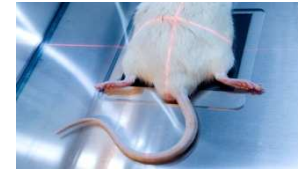


→ Ectopic bone formation

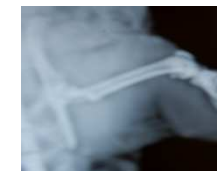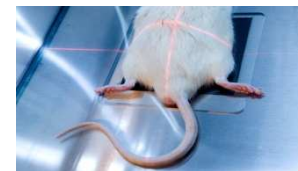* Necrotic area



Synopsis (example)



Rat experimental model of osteosarcoma - ABS



Ronan LE BOT – CEO

ronan.lebot@atlantic-bone-screen.com

Florence DAUBINE, PhD – Project Manager

florence.daubine@atlantic-bone-screen.com

Fabien PETIT – Project Manager

fabien.petit@atlantic-bone-screen.com

Elisabeth PORCHER – Business Development Manager

elisabeth.porcher@atlantic-bone-screen.com

ATLANTIC BONE SCREEN SAS

1, rue Gaston Veil

44000 Nantes

France

www.atlantic-bone-screen.com

Tel : +33(0)2 40 41 11 25

Fax : + 33(0)2 40 41 28 35

Contact us...

... And we will send you a tailor-made protocol study